

EFFECTS OF LEAD NITRATE ON THE TESTIS OF ADULT WISTAR RATS

ABSTRACT

Introduction The aim of this study was aimed at evaluating the effects of lead nitrate on adult wistar rats.

Methodology A total of 32 adult wistar rats weighing between 200 and 240g were divided into 4 groups of 8 rats per group. The control groups (group A) were placed on normal diet, while Group B rats received 35mg/ kg body weight / day of lead nitrate via orogastric tube. Group C rats received 45mg / kg body weight/ day of lead nitrate via orogastric tube. Group D rats received 50 mg/ kg body weight/ day of lead nitrate via orogastric tube and all the dosage were given for 40 days.

Results The results in group A, B, C and D showed normal histologic testicular architecture as evidenced by normal seminiferous tubules and interstitial spaces in figure 1, 2, 3 and 4.

Conclusion It was concluded that lead nitrate at 35mg/kg, 45mg/kg and 50mg/kg body weight/day was not toxic to the testis of an adult Wistar rats.

Keywords; *Lead nitrate, Wistar rat, Histology, Testis*

EHIMIGBAI Richard

Department of Anatomy,
Faculty of Basic Medical
Science,
College of Medical Science,
University of Benin,
Benin City,
Edo State.

corresponding author email:

ehirichard22@yahoo.com

INTRODUCTION

It has been earlier demonstrated that exposure to lead nitrate may result in an extensive alteration in biochemical, behavioral and physiological functions.¹ Lead is a heavy metal commonly used in the constitution of several industrial products. contact with compounds developed from lead may result in serious occupational hazards.² Studies relating the effects of exposure to lead nitrate to poisoning in developing countries have been well documented by several authurs.³⁻⁶ These hazardous effects of lead nitrate in the third world countries if not managed early may result in endemic consequences on both the present and possibly, future generations.

Studies relating the effects of exposure to lead nitrate to poisoning in developing countries have been well documented by several authurs.³⁻⁶ These hazardous effects of lead nitrate in the result in endemic consequences on both the third world countries if not managed early may present and possibly, future generations.

Liver has been demonstrated as the main target organ for many toxicants like lead.⁷ Chelating agents have been documented to be the most effective methods for managing exposure to lead toxicity. Chelators are known to form insoluble complexes with lead nitrate which prevent interactions with the target organ or site, thereby decreasing its toxicity.⁸ In practice however, these chelating agents are strongly toxic⁸ and highly lipophobic thereby preventing them from crossing the cell membrane to attack the intracellular lead.^{9,10}

Though few earlier studies have documented the ameliorative effects of some extracts on body tissues,^{11,12} the general notion is that exposure to lead nitrate may result in permanent tissue damage. The aim of this study was to determine the acute and chronic effects of exposure to lead nitrate on the testis of adult Wistar rat.

MATERIALS AND METHODS

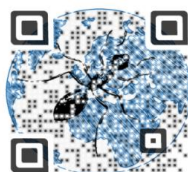
The lead nitrate was purchased from Patanne Chemical Limited, Benin City, Edo state, Nigeria.

EXPERIMENTAL DESIGN

The experimental animals used for this study were composed of thirty-two (32) adult male Wistar rats, weighing between 190 g and 220 g. They were obtained from the Animal Holdings of

Access this article online

Quick Response Code



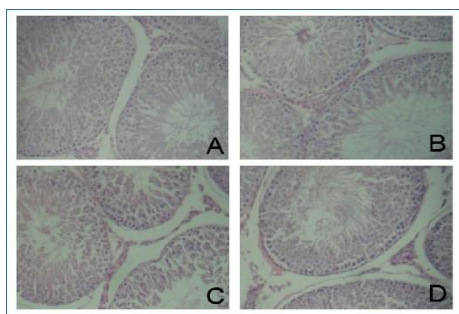
<http://ijfmi.com/index.php/home/article/view/9>

Department of Anatomy, School of Basic Medical Sciences, University of Benin, Benin city, Edo state, Nigeria. The test animals were allowed to acclimatize for 2 weeks. The rats were allowed free access to rat chow and water during acclimation and the period of the experiment.

The experimental model was in accordance with the National Institutes of Health Guide for the care and use of laboratory animals (NIH, 2002 publication, No. 83-23), (Revised 1978). The animals were grouped into 4 groups of 8 rats each. Group A rats served as control that were administered with only water and rat feed for 35 days. Group B rats were treated daily with oral administration of 35 mg / kg body weight lead nitrate only, for 40 days. Group C animals were treated with oral administration of 40 mg / kg body weight of lead nitrate only, for 40 days. Group D animals were treated with oral administration of 50 mg / kg body weight of lead nitrate only, for 40 days. Administration of the lead nitrate was performed orally, once daily using a metal cannula attached to a 1.0 ml syringe. The animals were anaesthetized using chloroform inhalation on the 41th days of experiment. A midline incision was made on the abdomen using a surgical blade and the testis were dissected out and fixed in bouin solution for histological analysis using standard techniques.^{13,14}

Photomicrography: The sectioned testicular tissues were viewed under Leica DM750 research microscope with a digital camera (Leica ICC50) attached. Digital photomicrographs of the tissue sections were taken at the Department of Anatomy, School of Basic Medical Sciences, University of Benin, Benin-City, Edo State, Nigeria.

RESULTS



Photomicrograph of rat testis. (a) composed of normal seminiferous tubules A and interstitial space B (control group). (b) The testis at 35mg/kg body wt/day of lead nitrate also consist of normal seminiferous tubules A and interstitial space B (H&E x 10). (c) It composed of normal seminiferous tubules A and interstitial space B (administered with 45mg/kg body wt /day of lead nitrate for 40 days). (d) The testis at 50mg/kg body wt/day of lead nitrate

composed of normal seminiferous tubules A and interstitial space B (H&E x 10). These testicular lumens were occupied with abundant and viable sperm cells, no distorted spermatids, with abundant mature sperm cells.

DISCUSSION

It has been documented that lead crosses the blood-testis barrier resulting in testicular damage by inducing lipid peroxidation, oxidative stress and production of reactive oxygen species which may damage the biological membranes in the testes with degeneration of the spermatogenic and Leydig cells.¹⁵⁻¹⁷ Lead nitrate has been shown to accumulate in the reproductive system resulting in a decreased number of spermatogenic cells a consequence of oxidative damage in the animal models.^{18,19}

A similar observation was reported in the study of lead toxicity by EL-Tohamy and El-Nattat (2010) who treated rats with lead acetate at the dosage of 10.8 and 15 mg/kg body weight and noticed deficiency in male reproductive activity through decrease in the sperm volume, sperm count, sperm motility and elevated sperm abnormality. However, these lead acetate action were amended by vit C addition into drinking water of the rat daily.²⁰

This present work was contrary to those of EL-Tohamy *et al* because exposures as low as 35mg /kg of lead nitrate administration, 45mg /kg of lead nitrate administration and 50mg/kg body weight per day to the rat did not showed significant changes in the histology of the testis of the adult male Wistar rats.²¹ The possible explanation for the differences in this work and previous studies may be attributed to several factors including time of administration, climate changes, mode of administration.

It can then be concluded that lead nitrate when given to adult Wistar rat at the dose of 35mg/kg, 45mg/kg and 50mg/kg respectively may not have any negative effect on the architecture of the testis.

REFERENCES

1. Courtois E, Marques M and Barrientos A. Lead-induced down-regulation of soluble guanylatecyclase in isolated rat aortic segments mediated by reactive oxygen species and cyclooxygenase-2. *J Am Soc Nephrol.*2003; 14(6):1464-1470.
2. Ahmed YF, Eldebaky HAA, Mahmoud KGM, Nawito M. Effects of lead exposure on DNA damage and apoptosis in reproductive and vital organs in female rabbits. *Global Veterinaria.* 2012; 9: 401-408.
3. Parikh DJ. Human exposure assessment to lead, an overview in India. *Indian J Indus Med.* 990;36:63-75.

4. Needdleman H. History of lead poisoning in the world. In: Lead poisoning prevention and treatment: Implementing a national programme in developing countries. February 8-10, Bangladesh, India. Proceedings of the International Conference on Lead Poisoning Prevention and Treatment 1990; 17-25.
5. Romieu I, Lacasann M and McConnel R. Lead exposure in Latin America and the Caribbean. Environmental Health Perspective. 1997; 105: 398 - 405.
6. Krishnaswamy K and Kumar BD. Lead toxicity. Indian J Pediat. 1998;35:209-216.
7. Meyer SA, Kulkarni AP. Hepatotoxicity. In: Hodgson E, Smart RC, editors. Introduction to biochemical Toxicology. 2001 vol. 3. New York: John Wiley. 487-490
8. FloraSJ, Saxena G and Mehta A. Reversal of lead-induced neuronal apoptosis by chelation treatment in rats: Role of ROS and intracellular Ca²⁺. J Pharmacol Exp Ther. 2007; 322 (1):108-116.
9. Ding GS and Liang YY. Antidotal effects of dimercaptosuccinic acid. J of Appl Toxicol. 1991;11:7-14.
10. Bosque MA, Domingo JL, Corbella J, Jones MM, Singh PK. Developmental toxicity evaluation of monoisoamyl meso-2,3-dimercaptosuccinate in mice. J Toxicol Environ Health. 1994; 42:443-540.
11. Ehimigbai ARO, Grillo-Baxter D, Gerald IE, Ezeuko CV. Protective effect of ethanolic extract of leaves of *Mormodicacharantia* on Lead nitrate induced Bone marrow toxicity in adult wistar rats. J Exp Clin Ana. 2015; 14(1): 13-17.
12. Ehimigbai ARO and Sakpa LC. Ameliorative effect of ethanolic extract of leaves of *Momordica charantia* on lead nitrate induced kidney damage in adult wistar rats. Ann Biomed Sci 015;14 (2):107-119.
13. Arthur SJ and John B.A Colour Atlas of Histopathological Staining. Wolfe Med. Pub.Ltd. London, 1978; Pp. 14-20.
14. Igale, GO, Olaszek W, Burda S and Jurzyska M. Nutritional Assessment of *Vernonia amygdalina* leaves in Growing Mice. J. Agric. Food Cem.1995; 143: 2162- 2166.
15. Wang, C., Zhang, Y., Liang, J., Shan, G., Wang, Y. and Shi, Q.(2006). Impacts of ascorbic acid and thiamine supplementation at different concentrations on lead toxicity in testis. ClinChimActa.; 370: 82-88.
16. Sainath, S.B., Meena, R., Supriya, C.H., Reddy, K.P. and Reddy, P.S.(2011). Protective role of *Centella asiatica* on lead-induced oxidative stress and suppressed reproductive health in male rats. Environ Toxicol Pharmacol.; 32: 146-154.
17. Dirican EK andKalenderY. Dichlorvos induced testicular toxicity in male rats and the protective role of vitamins C and E. Exp Toxicol Pathol.2012; 64: 821-830.
18. Fahim MA, TariqS, Adeghate E. Vitamin E modifies the ultrastructure of testis and epididymis in mice exposed to lead intoxication. Ann Anat.2013; 195: 272-277
19. Xiang D, Zhu J, Jin S, Hu Y, Tan F, Yang W. Expression and function analysis of Metallothionein in the testis of *Portunus trituberculatus* exposed to cadmium. Aqua Toxicol.2013; 140-141: 1-10
20. El-Tohamy, MM, El-Nattat WS, 2010. Effect of antioxidant on lead -induced oxidative damage and reproductive dysfunction in male rabbits. J. Am. Sci. 2010; 6(11): 613-622

How to cite this article: Ehimigbai R; Effects of Lead Nitrate on The Testis of Adult Wistar Rats; Int. J of Forensic Med Invest 2016; 2(1)5-7