

## A MORPHOMETRIC STUDY OF PTERION IN ADULT HUMAN DRY SKULLS IN THE ANATOMY MUSEUM AT THE DELTA STATE UNIVERSITY, ABRAKA, DELTA STATE

Anibor Ese, \*Obaroefe Martins, Nwaokoro Isioma Cynthia, Kainti Funkekeme Christopher

Department of Anatomy, Faculty of Basic Medical Sciences, Delta State University, Abraka

QR CODE



Website:  
<https://ijfmi.org>

<sup>1</sup>corresponding author  
email:  
[obaromartins@yahoo.com](mailto:obaromartins@yahoo.com)

### ABSTRACT

**Introduction:** This study was carried out at the Delta State University, Abraka in Nigeria, to ascertain the different forms of pteria and delineate their distances to adjoining structures in human skulls.

**Materials and Methods:** The study adopted a prospective descriptive mode and was conducted in the Department of Human Anatomy and Cell Biology, Delta State University, Abraka, Nigeria. A total of fifteen human skulls regardless of their gender in were used. Measurements on both sides of the skulls were taken using vernier calipers from the pterion to middle point of the zygoma and the frontozygomatic suture and reported on data sheet. The data was analyzed and presented in tables and charts.

**Results:** The most prevalent form of pterion seen was sphenoparietal pterion (n = 20; 66.7%) while the least was epipteric (n = 4; 13.3%). Frontotemporal pterion (n = 6; 20%) was also observed. The dimension of the pterion from the frontozygomatic suture was  $2.49 \pm 0.44$ cm on the left and  $2.51 \pm 0.29$ cm on the right. The pterion measurement from the middle of the zygomatic arch was  $4.04 \pm 0.35$ cm on the left and  $4.11 \pm 0.42$ cm on the right. There was no significant difference ( $p > 0.05$ ) between the right and the left sides.

**Conclusion:** Sphenoparietal pterion was the most widespread and the least epipteric. The stellate form was not found in the Anatomy Museum.

**Keywords:** Pterion, landmarks, dry, human, skulls

## INTRODUCTION

The floor of the temporal fossa is bounded to the upper part by the frontal and parietal bones, to the lower part by the wider wing of the sphenoid and squamous part of the temporal bone. All four bones on one hand meet at an H-shaped sutural junction known as pterion. It is an important neurosurgical and anthropometric landmark in the temporal fossa, where the facial skeleton, calvarium and skull base meet. Pterion is defined as the focal point

of the skull base, the calvarium and the facial skeleton.<sup>[1]</sup>

The pterion's location is around 4 cm above the zygomatic arch and 3.5 cm behind the frontozygomatic suture, giving the neurosurgeon a rather significant landmark. Among anthropologists and forensic pathologists, pterion has generated a great deal of

interest, as there are numerous types of pteria that have been found in different population groups.<sup>[2]</sup>

The pterion is regarded as the weakest section of the skull, but overlaps with the path of the anterior division of the middle meningeal artery, thus it is prone to rupture, with extradural hematoma after blunt injury to lateral part of the head.<sup>[3,4]</sup> This sutural point serves as a vital marker in the identification of the Broca Motor Speech Area, the anterior pole of the insular cortex, and the central cerebral artery.<sup>[5]</sup> the primary place to obtain access to the sphenoid ridge and optical canal during surgery.<sup>[6,7]</sup>

The pterion is also a significant landmark for the island of Reil and the stem of the lateral sulcus. Pterion is often widely used as an effective age guide by a cranial suture closure technique. The optional or lateral method is infrequently employed in surgeries concerning the Broca Motor Speech Area and in the reconstruction of aneurysms of the central cerebral artery.<sup>[8]</sup>

A hard blow to the lateral region of the head will crack the thin bones that make up the pterion, with a possible rupture of the artery that crosses the pterion, resulting to hematoma exerts pressure on the underlying cerebral cortex, with severe consequences if not treated for a few hours.<sup>[9]</sup> Various classifications of the pterion have been proposed<sup>[10,11]</sup>. Murphy identified four forms (frontotemporal, sphenoparietal, epipteric, and stellate).<sup>[10]</sup> Wang et al., identified six classifications (frontotemporal, sphenoparietal, epipteric, stellate, zygomaticotemporal and zygomaticoparietal).<sup>[11]</sup>

Differences in the exact pterial position have been identified between different races and might be owed to hereditary or ecological factors influencing the craniometric indices of the human skull.<sup>[12]</sup> Various population-based studies are also needed to provide appropriate local data for different populations. This study was carried out at the Delta State University, Abraka in Nigeria, to ascertain the different forms of pteria and delineate their distances to adjoining structures in human skulls. This survey also intends to

assess if any association exist between pterion types and side of the skull.

## MATERIALS AND METHODS

### Ethical Clearance

Ethical clearance was obtained from the Research and Ethics Committee of Anatomy and Cell Biology Department in the Delta State University, Abraka.

### Sampling Techniques

Purposive sampling technique was used for this research and a total of 15 human skulls with an unknown gender and age found in the Anatomical Museum of Anatomy and Cell Biology Department, Delta State University, were the sample sizes of this study.

### Subject Selection Criteria

Inclusion requirements included adult human skulls, irrespective of gender, with intact calvaria and well-defined sutures. Exclusion criteria included damaged skulls and very old skulls with obliterated sutures.

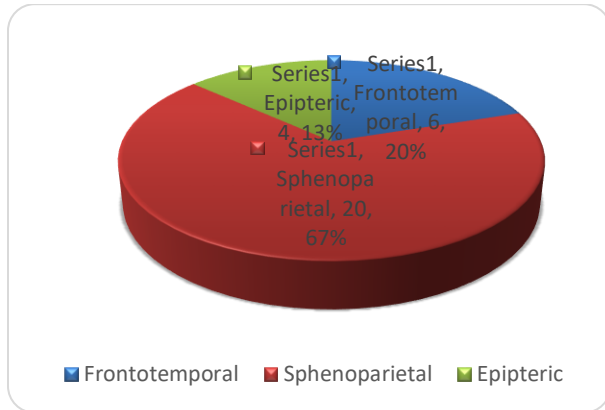
### Data Collection

Pteria were classified by Murphy's classification. Measurements were made on both sides of the skull from the middle of the pterion to the middle of the zygoma process of the temporal bone and the frontozygomatic suture using 0,01 mm vernier callipers. Each measurement was carefully taken and recorded on the data collection sheet.

### Statistical Analysis

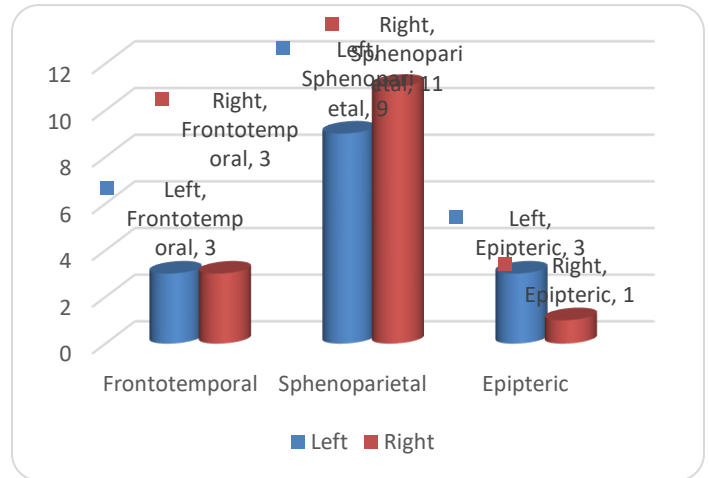
Data were analyzed using version 23 of the Statistical Package for the Social Science (SPSS). The findings were then described in basic percentages, frequency, mean  $\pm$  standard deviation for the descriptive statistics, and the Mann-Whitney test was used to test the statistical difference between the left and the right sides of the skulls.

## RESULTS



**Figure 1: A pie chart show the distribution of various types of pterions**

Figure 1 indicates the distribution of the different sorts of pterion. The most prevalent form of pterion seen was sphenoparietal pterion (n = 20; 66.7 per cent) while the least was epipteric (n = 4; 13.3 per cent). Frontotemporal pterion (n = 6; 20%) was also observed.



**Figure 2 Side distributions of the various pterion types**

Figure 2 shows the side distribution of the pterion types. Sphenoparietal was more prevalent on the right (n=11; 36.6 per cent) while epipteric was less prevalent on the right (n=1; 3.3 per cent). The frontotemporal type was equally seen on the left and right sides (n = 3; 10%).

**Table 1: Descriptive statistics of the distances between the pterion and other landmarks**

	Side	Minimum	Maximum	Mean ± SD	P – value
FZ	L	2.0	3.50	2.49 ± 0.44	0.653
	R	2.0	3.30	2.51 ± 0.29	
MZ	L	3.40	4.60	4.04 ± 0.35	0.624
	R	3.40	4.80	4.11 ± 0.42	

FZ = Frontozygomatic suture

MZ = Midpoint of the zygomatic arch

L = Left

R = Right

Table 1 displays the descriptive statistics on the location of the pterion from the frontozygomatic suture as well as the middle of zygomatic arch. The distance between the

pterion and the frontozygomatic suture was  $2.49 \pm 0.44$ cm on the left and  $2.51 \pm 0.29$ cm on the right. The distance between the pterion and middle of the zygomatic arch was

4.04 ± 0.35cm on the left and 4.11 ± 0.42cm on the right. No statistically significant difference (p>0.05) was observed between the right and the left sides, in the distance of the pterion from the middle of the zygomatic arch as well as the frontozygomatic suture.

## DISCUSSION

It is important to learn about pterional location and its relationship to nearby bony landmarks, as pterional craniotomy is one of the most common and resourceful techniques used by neurosurgeons to gain access to brain and tumor lesions, sylvian fissure, parasellar regions, upper orbital fissure, sphenoidal wing, cavernous sinus, orbit, optic nerve, mesial fissure [13, 14, 15, 16]

In this current research, three forms of pterion were noted, including: frontotemporal, sphenoparietal and epipteric. No stellate pterion was observed and sphenoparietal pterion was frequent (n = 20; 66.7 per cent). The prevalence of frontotemporal pterion was 20% (n=6), while the least prevalence was epipteric (n=4; 13.3 per cent). Similar findings have been reported in other Nigerian populations where the sphenoparietal form divulged frequentness of 72%, followed by fronto temporal (18%) and the least popular was epipteric (2 percent ).<sup>[17]</sup> Western Nigerians found that sphenoparietal (86 per cent) was the most common but did not find epipteric variety.<sup>12</sup> Southern Nigerians recorded 83 per cent sphenoparietal, 6% stellate, 6% epipteric, and 5% frontotemporal forms in their study.<sup>[18]</sup> In the Japanese population, Scholars recorded 79.1% prevalence of sphenoparietal pterion, 17.7% stellate, 2.6% frontotemporal and 0.6% epipteric.<sup>[19]</sup> Anthropologists reported a 76.5% prevalence of sphenoparietal in the Korean population, while Surgeons reported an 88% prevalence of sphenoparietal in the Turkish population, Morphologists reported a 66% prevalence in the Kenyan population.<sup>[20, 21, 22]</sup> The Asians also found that sphenoparietal (75.41%) was the most common, while epipteric (13.11%) was more common than frontotemporal (6.55%) and stellate (4.91%).<sup>[23]</sup> Northwest Indians registered a maximum number of epipteric types 21.7% on the right and 26.0% on the left.<sup>[24]</sup> Southern Indians also confirmed that the sphenoparietal was the most frequent and frontotemporal the least incident

(3%).<sup>[25]</sup> The sphenoparietal form of pterion was found to be widespread on Nigerian skulls and those of different races, such as Indians, Turks, and Kenyans.<sup>[6, 21, 22]</sup>

The mean distance from the pterion to the frontozygomatic arch (FZ) was 2.49 ± 0.44 cm for left and 2.51 ± 0.29 cm for right. There was however, no statistically significant difference between the two sides. The position of the pterion from the middle of the zygomatic arch was 4.04 ± 0.35 cm on the left and 4.11 ± 0.42 cm on the right. There was no statistically significant difference (p>.05) between the sides. This is consistent with the studies of Eastern Nigerians, Southern Nigerians, Southern Indians, North Indians, Southern Asians and Hindus (2010).<sup>[17, 18, 26, 27, 28, 29]</sup>

The differences between the various studies highlighted above may be attributed to genetic and environmental factors.

## CONCLUSION

The morphometry of the pteria in skulls at the Anatomy Museum of the Delta State University, Abraka, Delta State, were studied. Sphenoparietal pterion was found to be the most prevalent, the least was epipteric and stellate form was not found.

## REFERENCES

1. Standring, S., Ellis, H., Healy, J. C. and Johnson, D. (2005). *Gray's Anatomy-The Anatomical Basis of Clinical Practice. 39th ed. London, Elsevier Churchill Livingstone, pp.441-84.*
2. Seema, D., Dakshayani, K.R. and Sumanth, M.M. (2013). *A Morphometric Study of Pterion in Adult Human Skulls. International Journal of Recent Trends in Science and Technology. 9 (1).*
3. Williams, P.L., Bannister, L.H., Berry, M.M., Collins, P., Dyson, M. and Dussek, J.E. (1998).

- Gray's Anatomy, Churchill Livingstone, London, UK, 38th edition.*
4. Lama, M., Mottolese, C., Alvisi, C. and Riccio, A. (2000). Middle meningeal artery aneurysm associated with meningioma. *Journal of Neurosurgical Sciences*, 44 (1): 39–41.
  5. Apinhasmit, W., Chompoopong, S., Chaisuksunt, V., Thiraphatthanavong, P. and Phasukdee, N. (2011). Anatomical consideration of pterion and its related references in Thai dry skulls for pterional surgical approach. *Journal of the Medical Association of Thailand*, 94 (2): 205–214.
  6. Saxena RC, Bilodi AK, Mane SS, Kumar A. Study of pterion in skulls of awadh area-in and around Lucknow. *Kathmandu Univ Med J (KUMJ)* 2003; 1:32-3.
  7. Urzi F, Lannello A, Torrisi A, Foti P, Mortellaro NF, Cavallaro M. Morphological variability of pterion in the human skull. *Ital .J. Anat. Embryol*; 2003; 108 (2): 83-117.
  8. Escosa-Bage, M., Sola, R.G., Liberal-Gonzalez, R., Caniego, J.L. and Castrillo-Cazon, C. (2002). Fusiform aneurysm of the middle cerebral artery. *Revista de Neurologia*, 34(7): 655–658.
  9. Moore, K.L. and Dalley, A.F. (2006). *Clinical Oriented Anatomy. 5th ed. Philadelphia, Lippincott Williams & Wilkins, pp.887-903.*
  10. Murphy, T. (1956). The pterion in the Australian aborigine. *American Journal of Physical Anthropology*, 14(2):225-44.
  11. Wang, Q., Opperman, L. A., Havil, L. M., Carlson, D. S. and Dechow, P.C. (2006). Inheritance of sutural pattern at the pterion in Rhesus Monkey skulls. *Anatomical Record Discoveries in Molecular and Cellular Evolutionary Biology*, 288(10):1042-9.
  12. Adejuwon, S.A., Olopade, F.E. and Bolaji, M. (2013). Study of the Location and Morphology of the Pterion in Adult Nigerian Skulls. *International Scholarly Research Notices Anatomy*. 40(3): 93-97.
  13. Ersoy, M., Evliyaoglu, C., Bozkurt, M.C., Konuskan B, Tekdemir I, Keskillis (2003). Epipteric bones in the pterion may be a surgical pitfall. *Minim Invasive Neurosurgery*. 46: 363-5.
  14. Cheng, W.Y., Lee, H.T., Sun, M.H. and Shen, C.C. (2006). A pterion keyhole approach for the treatment of anterior circulation aneurysms. *Minimal Invasive Neurosurgery* 49: 257-62.

15. Chao, S.C., Shen, C.C. and Cheng, W.Y. (2008). *Microsurgical removal of sylvian fissure lipoma with pterion keyhole approach – Case report and review of literature. Surgical Neurology. 70 (1 I): S1-90.*
16. Sucharitha, A. and Bajpe, R. (2016). *Study of anatomic position of Pterion in dry human skulls in Karnataka. Scholars Journal of Applied Medical Sciences, 4(9B):3272-3276.*
17. Ukoha, U., Oranusi, C.K., Okafor, J.I., Udemezue, O.O., Anyabolu, A.E. and Nwamarachi, T.C. (2013). *Anatomic study of the pterion in Nigerian dry human skulls. Nigerian Journal of Clinical Practice, 16:325-8.*
18. Eboh, D.E.O. and Obaroefe, M. (2014). *Morphometric study of pterion in dry human skull bones of Nigerians. International Journal of Morphology, 32(1):208-213.*
19. Matsumara, G., Kida, K., Ichikawa, R. and Kodama, G. (1991). *Pterion and epipteric bones in Japanese adults and fetuses with special reference to their formation and variations. Acta Anatomica Nipponica; 66:462-471.*
20. Lee, U.Y., Park, D.K., Kwon, S.O., Paik, D.J. and Han, S.H. (2001). *Morphological analysis of the pterion in Korean. Korean Journal of Physical Anthropology, 14: 281-289.*
21. Oguz O, Sanli SG, Bozkir MG, Soames RW. (2004). *The pterion in Turkish male skulls. Surgical and Radiological Anatomy 26(3): 220-224.*
22. Mwachaka, P., Hassanali, J. and Odula, P. (2009). *Sutural Morphology of the pterion and asterion among adult Kenyans. Brazilian Journal of Morphological Science; 26 (1): 4-7.*
23. Yuvaraj, M., Pushkaran, J., Sankaran, P.K. (2017). *A morphometric study on different shapes of pterion and its clinical significance. International Journal of Pharmacological and Biological Science. 8(2):999-1003.*
24. Gupta, R., Sinha, M.B. and Aggarwal, A. (2014). *Landmarks for keyhole neurosurgical procedures through pterion. International Journal of Healthcare and Biomedical Research. 2(4):168-175.*
25. Praba, A.M., Venkatram, A. and Aniah C. (2012). *Morphometric study of different types of pterion and its relation with middle meningeal artery in dry skulls of Tamil Nadu. JPBMS, 21(21):1-4.*
26. Hussain, S.S., Mavishetter, G.F., Thomas, S.T., Prasanna, L.C. and Muralidhar, P. (2010).

- Anatomical position of pterion among the Indian for lateral skull approach. Biomedicine, 30 (3): 391-393.*
27. Hariprasad, N.K., Bezbaruah, A.M. and Parmatma, P.M. (2015). *Morphometric analysis of pterion: A clinic-Anatomical study in North Indian dry skulls. Innovative Journal of Medical and Health Science, 5 (5): 201-205.*
28. Seema, D. and Mahajan, A. (2014). *Pterion formation in North Indian population: an Anatomico-clinical study. International Journal of Morphology, 32(4):1444-1448.*
29. Suchit, K., Anurag, S. Munjal, P., Chauhan, A., Chaudary, S. and Kumar J. (2013). *Pterion-its location and clinical implication – A study compared. Journal of Evolution of Medical and Dental Sciences, 2 (25); 4599-4608.*